

L4-L5 Spinal Stenosis With Synovial Cyst Relieved with Cox[®] Decompression Adjusting Following Epidural Steroid Injection With No Help

79-year-old, white, retired female is seen in February 2005 for the chief complaint of left hip pain, bilateral shoulder pain, and pain extending down the left leg to the ankle. History shows that she had a rotator cuff surgery on the left shoulder in 2001 but following surgery, exercise caused the pain to recur and she again had a tear of the rotator cuff. She has been on a cholesterol lowering drug and felt that it caused muscle weakness and ache, and she stopped taking it about 1 year ago. The left hip pain first started in May, 2004 as an ache and the leg pain started after using the cholesterol lowering agent drugs. She had epidural steroid injections in November 2004 and again in January 2005 with no help. There is a history of breast cancer in 2003 and she underwent radiation treatment following surgery.

Vital signs are normal. Low back examination reveals +2 deep tendon reflexes globally, positive sitting straight leg raise causing low back and left lower extremity pain, positive Kemp's sign, hyperlordosis of the lumbar spine, marked pain on palpation from the L3 through L5 levels. The range of motion is within normal limits. No sensory findings are found of the lower extremities on pinwheel examination. Straight leg raise causes flexion of the left knee at approximately 60 degrees due to pain. The Patrick's sign on the left is very positive. No motor weakness is noted on dorsiflexion and plantar flexion of the great toe, and foot at the ankle. Gluteus maximus, biceps femoris, and quadriceps muscles are grade 5 of 5.

Cervical spine examination reveals flexion of 15 degrees, extension 15 degrees, right and left lateral flexion 10 degrees, and right and left rotation 20 degrees. There is marked loss of movement at the C4 through C6 levels, and great pain on palpation at the C2 level bilaterally. Hypesthesia of the left C6 and C7 dermatomes is noted. The range of motion of the shoulders is limited to 10 degrees of abduction on the left side due to surgical intervention. Deep tendon reflexes of the upper extremities are +2. Cervical compression is negative. No dermatome pain is complained of in the patient at this time, although there is hypesthesia noted on pinwheel examination.

Included are the MRIs of this patient, which are of the lumbar spine. We draw attention primarily to the L3-4 and L4-5 levels.

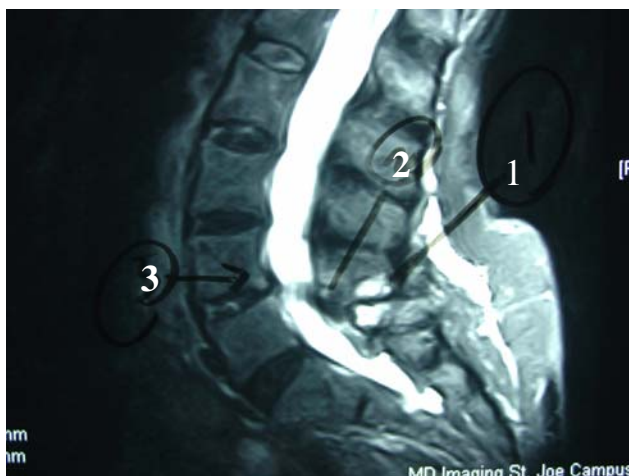


Figure 1 is the sagittal image of the lumbar spine demonstrating the L4 minimal degenerative spondylolisthesis of approximately 5% (see number 3 on image), interspinous ligament fluid accumulation (see number 1 on the image) and left ligamentum flavum thickening and the reading radiologist of this report states that there is a synovial cyst present at the L4-L5 level on the left (see number 1 on the image).

Figure 1

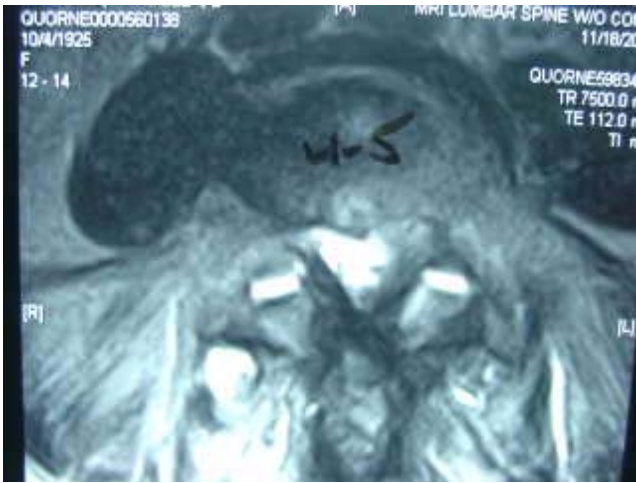

Figure 2

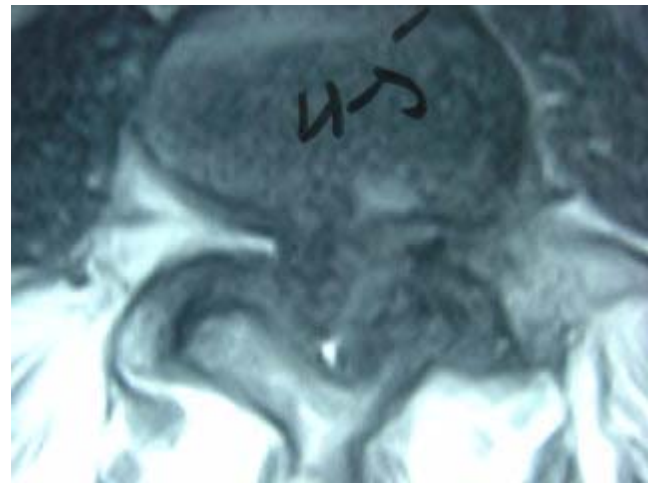


Figure 3

Figure 2 is an axial image at the L4-L5 level showing left osseoligamentous narrowing due to the changes best seen in Figure 3 which shows ligamentum flavum hypertrophy, a synovial cyst of the left sided facet joints with arthrosis of both the right and left facet joints to create marked stenosis of the left osseoligamentous canal. This combination of findings does create significant spinal stenosis of the left lateral recess and osseoligamentous canal, which is felt to account for the left lower extremity pain.

Following the MRI, facet joint block, interspinous ligament injection, and another epidural steroid injection was recommended. Instead the patient sought chiropractic care from our clinic and following two office visits consisting of Cox® Decompression Manipulation, followed by positive galvanism in the left L4-L5 facet joint, followed by tetanizing current to the paravertebral muscles, the patient stated that she felt improvement. By the fourth visit, her VAS pain of the low back and left hip, which had been rated at a 9, reduced to a 3 and 4 for hip and leg pain. Her shoulder pain also continued to improve with cervical Cox® Decompression adjusting, and electrical stimulation of the left rotator cuff supraspinatous tendon. Following one month of care, 10 office visits, this patient's left hip and leg pain was reduced to a VAS of 3. She was very happy with this clinical result which was superior to her past medical care including epidural steroid injections. You will note that we do not attain 100% relief of the pain, but relief that allows the quality of life that is compatible with patient wishes. Stenosis is not curable, but controllable.

I would point out that this is another example of radiographically diagnosed synovial cyst, which has yielded well to decompression adjusting. Remember that synovial cysts have classically been surgically removed. We have published papers, including one in the February 2005 issue of the *Journal of Manipulative and Physiological Therapeutics*, showing the relief of two cases of Synovial cysts. The relief of synovial cyst generated lower extremity pain has been very good with this decompression manipulation.

Respectfully submitted,
James M. Cox, DC, DACBR
Diplomate, American Chiropractic Board of Radiology
JMC/ jcs

www.coxtechnic.com

